

## Case Report

### Open bite treatment using clear aligners

Maria Paola Guarneri<sup>a</sup>; Teresa Oliverio<sup>b</sup>; Ivana Silvestre<sup>b</sup>; Luca Lombardo<sup>a</sup>; Giuseppe Siciliani<sup>c</sup>

#### ABSTRACT

A 35-year-old female patient with dentoalveolar open bite of 4 mm, molar Class I malocclusion, centered midlines, moderate crowding, and labial inclination of the lower incisor was treated with clear aligners to reduce protrusion and close the anterior open bite. The result showed that clear aligners were an effective method with which to correct this malocclusion. The treatment was complete after 18 months. The patient was satisfied with her new appearance and function. (*Angle Orthod.* 2013;83:913–919.)

**KEY WORDS:** Open bite; Clear aligners; Esthetic treatment; Adult patient

#### INTRODUCTION

Orthodontic treatment of open bite remains one of the most difficult challenges facing orthodontists today, as vertical incompetence of the arches due to poor dental and/or skeletal position does not permit correct occlusion between antagonistic teeth.<sup>1</sup> This lack of contact can be caused either by dentoalveolar anomaly or skeletal alteration, and the pathogenesis of open bite will determine the course of treatment, whether orthodontic or combined surgical and orthodontic. In fact, solely orthodontic intervention is an option only in cases of dentoalveolar alteration, whereas surgery is indicated in cases of skeletal dysgnathia.<sup>2</sup>

Many factors may lead to anterior open bite, including bad habits such as thumb- or dummy-sucking or unfavorable growth patterns, which are often correlated with a genetic or familiar predisposition. Authors<sup>3</sup> have suggested that excessive development of the lymphatic tissues may be partly to blame, but in general, the etiology of this type of malocclusion is multifactorial. In the case of growing patients in whom bad habits have contributed to the insurgence of anterior open bite, early intervention with

interceptive functional appliances or speech therapy may resolve or improve the clinical picture.

In adult patients, on the other hand, accurate diagnosis of the dentoalveolar or skeletal origin of the malocclusion, via cephalometric analysis of teleradiographical or tomographical scans, needs to be performed. In these cases, treatment options are numerous and involve maxillofacial surgery to correct skeletal open bite (the maxillary and mandibular planes are divergent with increased vertical facial height and inclined bispinal plane)<sup>4</sup>; intrusion of the posterior sectors to correct dental open bite due to overextrusion of the posterior sectors; or extrusion of the anterior dental sectors alone, especially in cases of poor vertical development in the premaxillary region.

#### Diagnosis and Etiology

A 35-year-old female patient presented with dentoalveolar open bite (Figure 1). The patient had previously treated with fixed appliances. Facial photographs showed a normal profile, with increased lower facial height and unstrained lip closure. Intraoral examination revealed an open bite of approximately 4 mm, molar Class I malocclusion with centered midlines and moderate crowding, measuring roughly 2 mm, on the upper and lower arches. Clinical examination revealed a tongue-thrust habit during speech and at rest. Cephalometric examination confirmed the Class I skeletal pattern<sup>5,6</sup> and labial inclination of the lower incisors (L1-protrusion) (Figures 2 through 4).

#### Treatment Objectives

The dental objectives of treatment for this patient were to correct the open bite by normalizing the overjet and overbite relationships with extrusion of anterior

<sup>a</sup> Assistant Professor, Postgraduate School of Orthodontics, University of Ferrara, Ferrara, Italy.

<sup>b</sup> Resident, Postgraduate School of Orthodontics, University of Ferrara, Ferrara, Italy.

<sup>c</sup> Professor and Chairman, Postgraduate School of Orthodontics, University of Ferrara, Ferrara, Italy.

Corresponding author: Dr Lombardo Luca, Assistant Professor, Postgraduate School of Orthodontics, University of Ferrara, Via Montebellou 31, Ferrara 44100 Italy (e-mail: lulombardo@tiscali.it)

Accepted: December 2012. Submitted: August 2012.

Published Online: January 30, 2013

© 2013 by The EH Angle Education and Research Foundation, Inc.



Figure 1. Extraoral pictures of the 35-year-old female patient treated with clear aligners.

teeth by preventing extrusion of the molars; to resolve crowding in both arches; and to establish functional occlusion.

### Treatment Alternatives

Based on the fact that no skeletal discrepancies were present, a combination of orthodontic and orthognathic surgical treatment was not considered. Treatment with fixed appliances and extraction of the maxillary and mandibular first premolars was considered, but the patient refused, as she had been treated previously with fixed appliances and did not want to repeat the experience. Therefore, the treatment of

choice involved clear aligners. In order to close the bite and to avoid affecting the other elements, the treatment plan called for approximately 4 mm of extrusion of the anterior teeth. Before starting orthodontic treatment, the patient was advised to undergo myofunctional therapy, and she was counseled that her cooperation was a critical factor in achieving success with aligner treatment.

### Treatment Progress

A series of 35 aligners for the upper arch and 15 for the lower was planned (Figure 5). In order to promote extrusion of the upper incisors, the shape of attach-

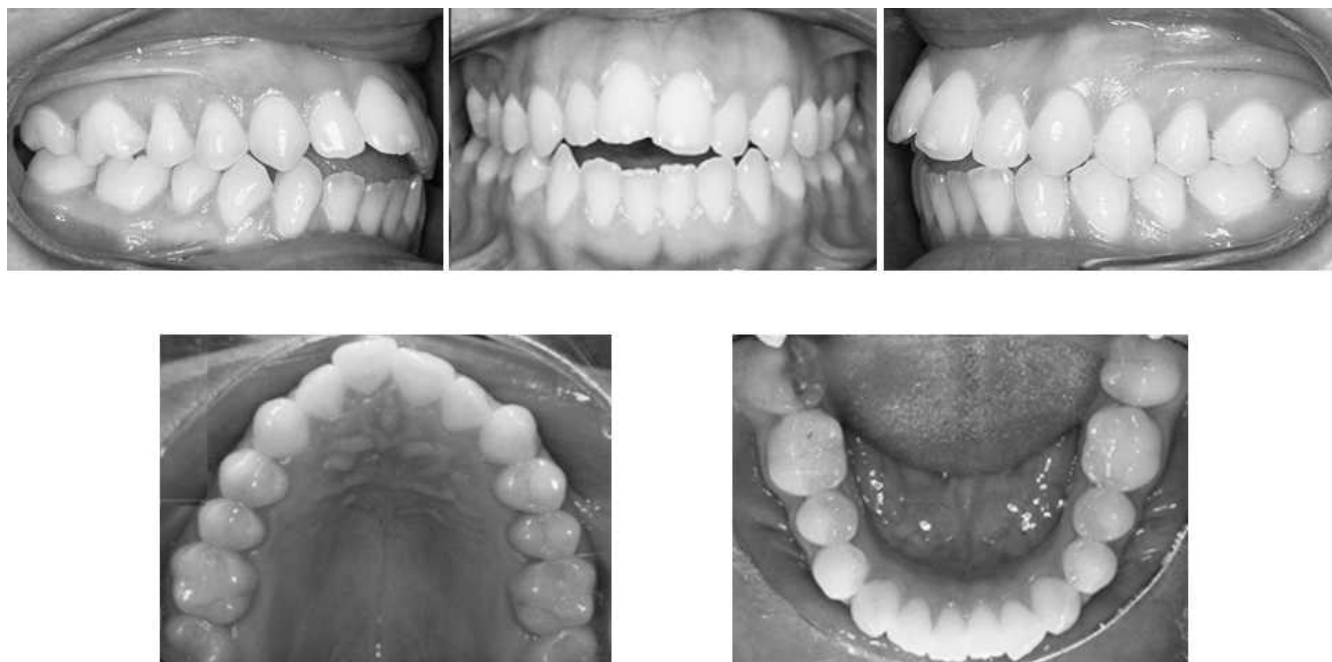
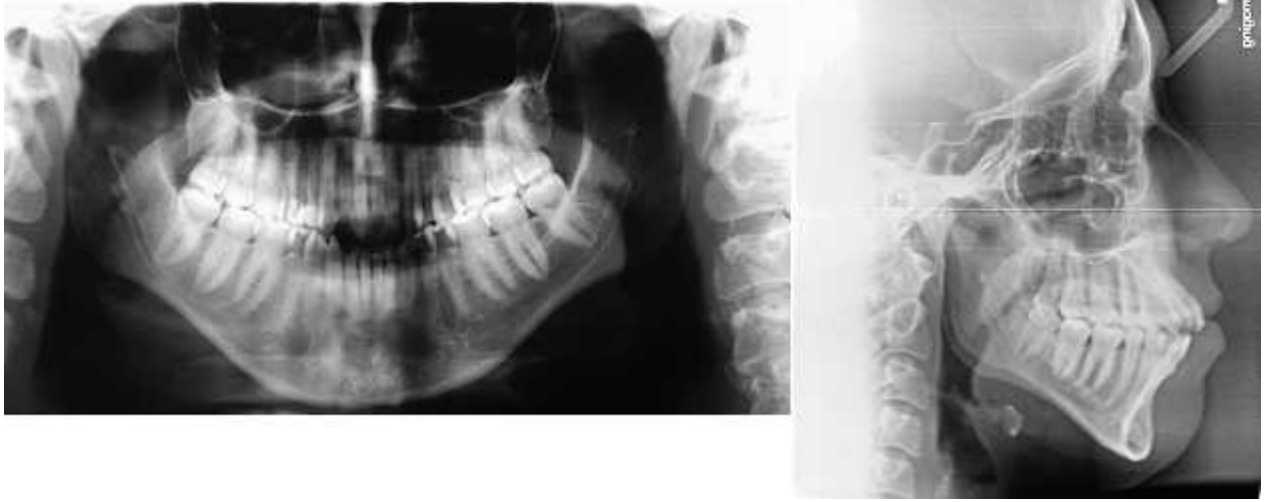


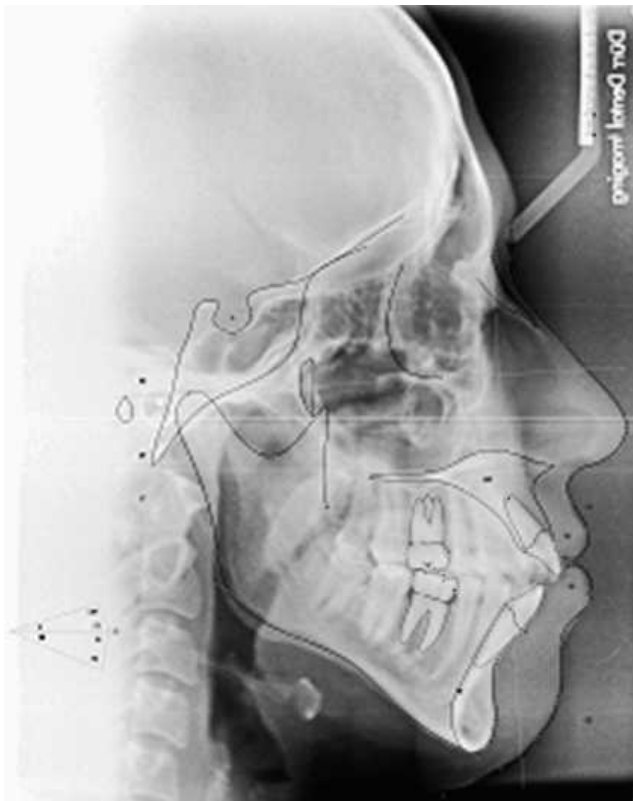
Figure 2. Intraoral pictures of the anterior open bite, Class I molar and canine relationship.



**Figure 3.** Pretreatment radiographs; Class I skeletal pattern.

ments was beveled horizontal rectangular, 1 mm thick on the gingival side and 0.25 mm thick toward the occlusal surface. On teeth 11, 12, 21, and 22, 0.2 mm of interproximal reduction was also necessary from canine to canine. One millimeter-thick ellipsoid attach-

ments were required for extrusion of teeth 31, 32, 41, and 42 in the lower arch. A beveled attachment of 1-mm distal thickness and 0.25-mm mesial thickness was necessary for 2° of derotation of tooth 43 per aligner<sup>7</sup> (Figures 6 and 7). The rate of extrusion was 0.12 mm per aligner, for a total of 3 mm on the upper incisors and 1 mm on the lower incisors. The treatment was completed after 18 months to full patient satisfaction. The patient wore aligners for retention.



**Figure 4.** Cephalometric tracing using the technique of Tweed and cephalometric values before treatment.

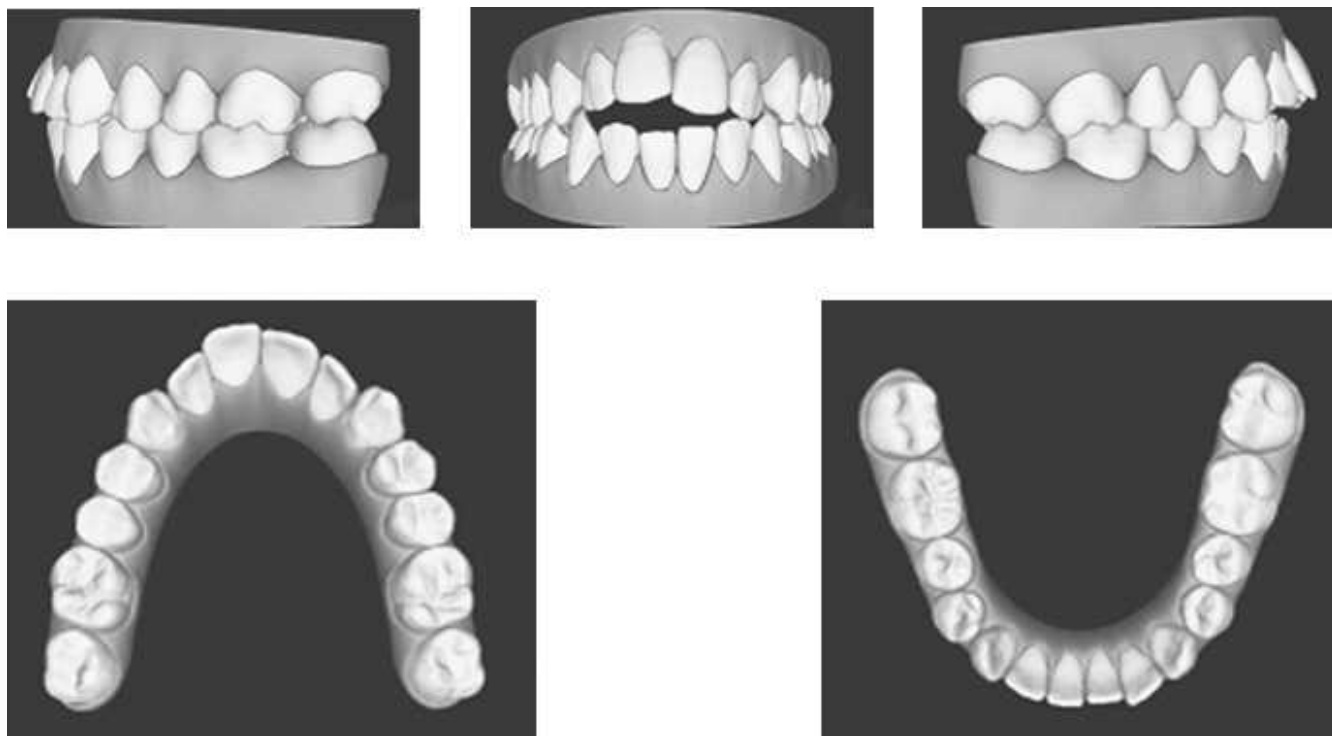
### Treatment Results

After 18 months of treatment, the anterior open bite had been completely closed; proper overbite and overjet had been established; and crowding of both arches was resolved. Cephalometric analysis showed the amount of relative extrusion of anterior teeth needed for closure of the open bite. The cephalometric changes included decreases in the ANB angle and Wits appraisal (Table 1).

Superimposition of the pretreatment and posttreatment cephalometric tracings showed that the overall skeletal structures and the mandibular plane angle remained remarkably similar throughout treatment (Figure 8), considering the closure of a substantial open bite.

### DISCUSSION

Several treatment approaches to open bite and many useful techniques can be found in the literature.<sup>8</sup> Like most orthodontic problems, the cause of open bite is usually multifactorial including unfavorable growth pattern, nasopharyngeal airway obstruction, and tongue posture and function.<sup>9</sup> The patient presented



**Figure 5.** Digital dental casts at the first stage of treatment.

here had a dental open bite with tongue posture problems and was treated with clear aligners. Aligner treatment has proved to be particularly effective in controlling anterior open bite because the double thickness of the clear plastic appliances on the occlusal surface, in combination with the patient's mastication force, exerted an intrusive force on the posterior teeth, with excellent results<sup>10</sup> (Figures 8 through 12).

Treatment with fixed appliances may also extrude the teeth, further opening the bite, especially when interarch elastics are used on the anterior teeth. Furthermore, many patients who request aligner

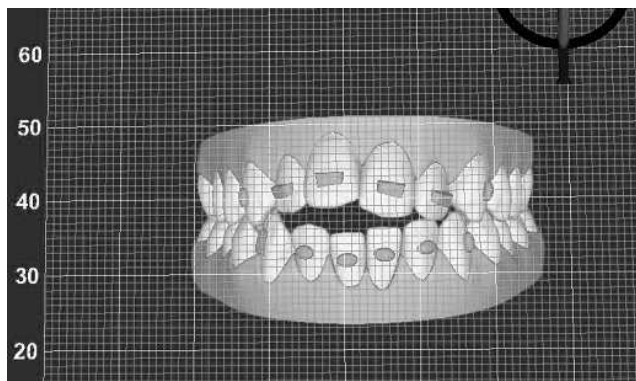
treatment have previously undergone orthodontic treatment with fixed appliances and do not want to repeat the experience.<sup>10</sup> A further advantage of this technique with respect to traditional methods is that the teeth not subject to dental movement remain anchored; the attachments are necessary and sufficient for the closure of open bite. However, a prerequisite is that the patient must be committed to strict compliance with a clear aligners regimen, which is essential to achieving good results. In addition, consultation with a myofunctional therapist becomes necessary before and during orthodontic treatment. The retention protocol for an open bite treated with clear aligners should be identical to that in a case treated with fixed appliances.<sup>11</sup>

## CONCLUSION

- This case report demonstrates how, for the first time, complex cases such as dentoalveolar open bite, which had previously been treated exclusively with fixed appliances, can be resolved efficiently—while simultaneously maintaining facial esthetics—using clear aligners.

## REFERENCES

1. Subtelny JD, Sakuda M. Openbite diagnosis and treatment. *Am J Orthod.* 1964;50:337–358.



**Figure 6.** Using the grid tool, the dental open bite reveals to be of 4 mm.

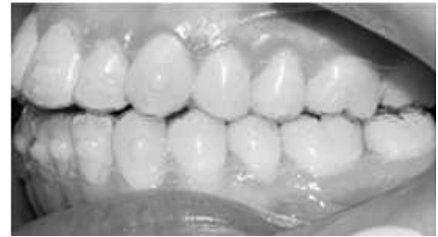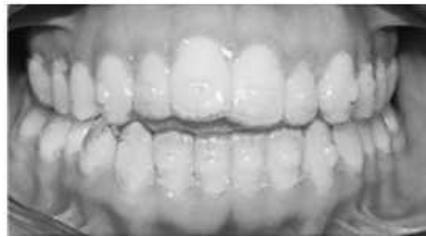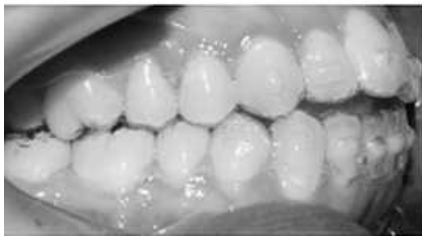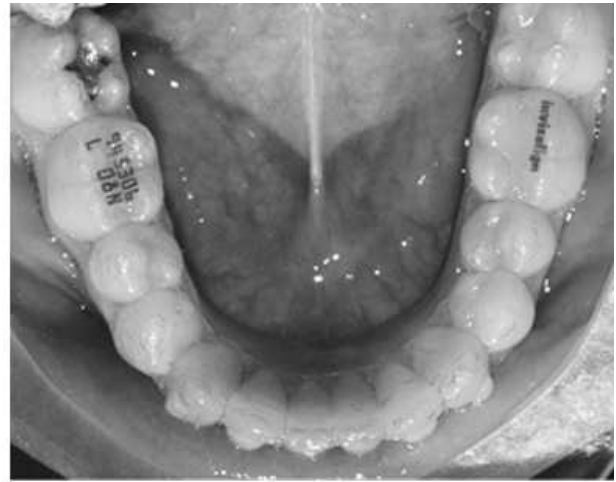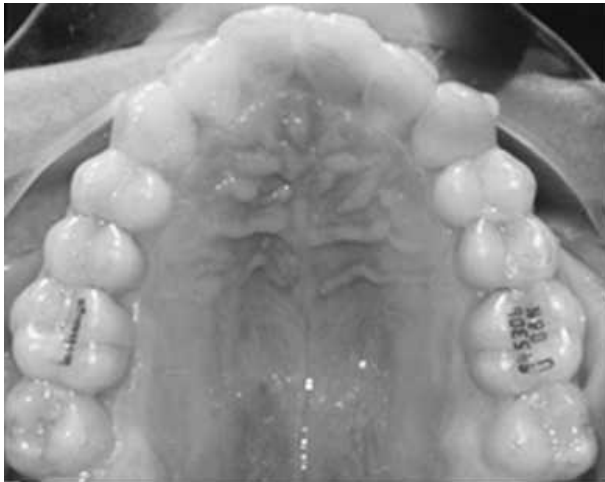


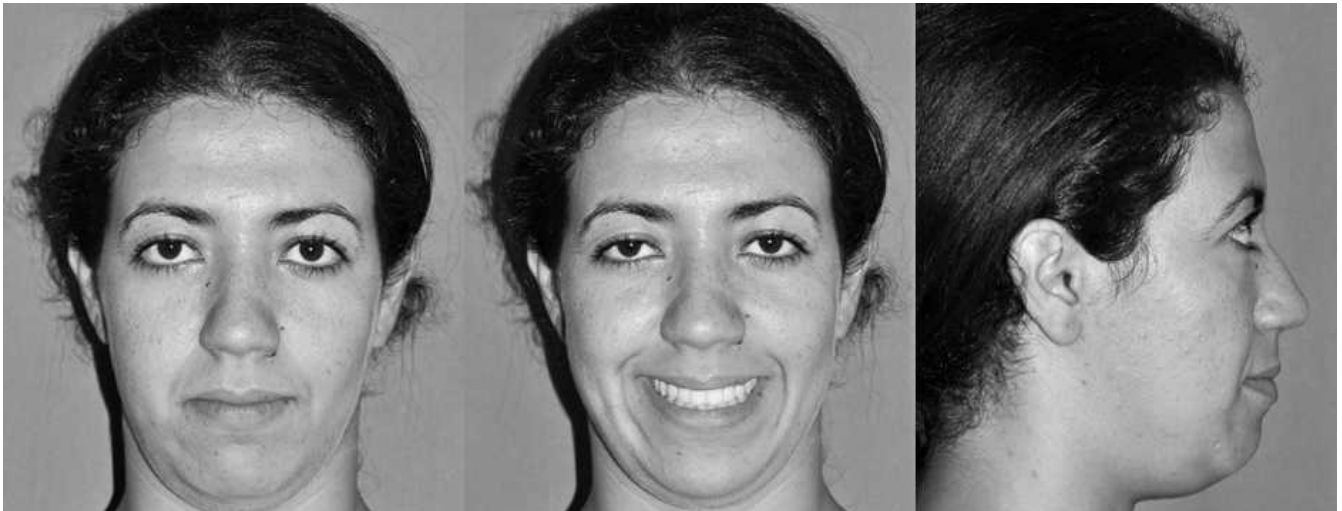Figure 7. Case in progress with aligners number 8 in both arches.

2. Nahoum HI, Horowitz SL, Benedicto EA. Varieties of anterior open bite. *Am J Orthod.* 1972;61:486–492.  
 3. Fujiki T, Inoue M, Miyawaki S, Nagasaki T, Tanamoto K, Takano-Yamamoto T. Relationship between maxillo-facial

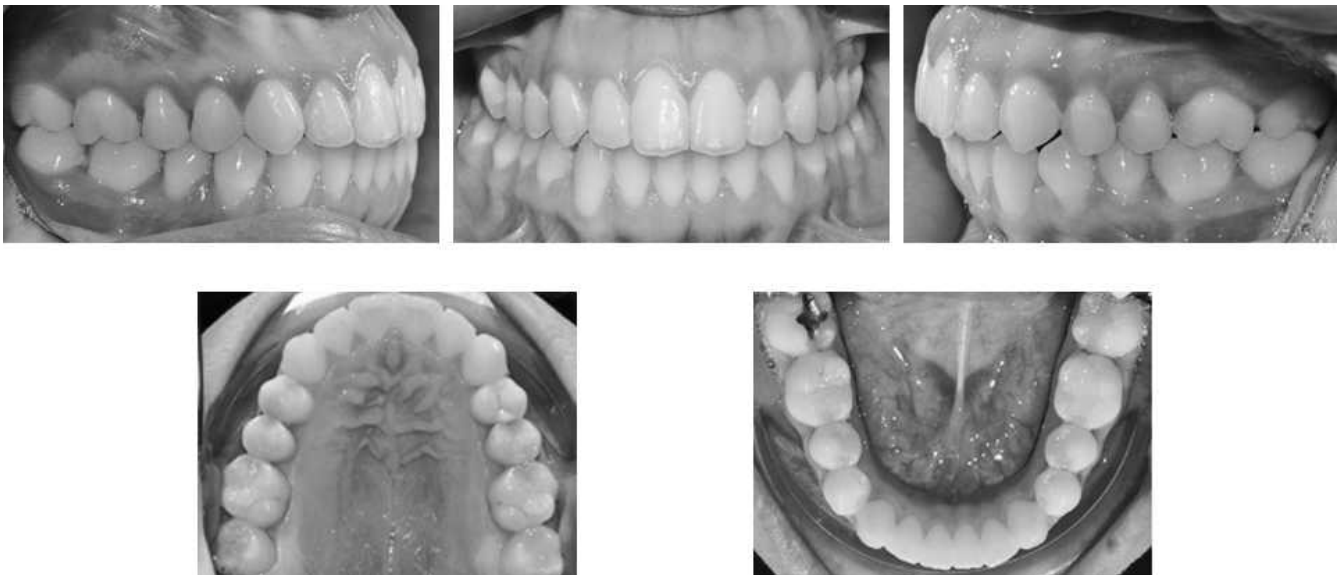
morphology and deglutitive tongue movement in patients with anterior open bite. *Am J Orthod.* 2004;125:160–167.  
 4. Nahoum H. Vertical proportions and the palatal plane in anterior open bite. *Am J Orthod.* 1971;59:273–282.  
 5. Salzman JA. *Radiographic Cephalometrics in Diagnosis and Treatment in Orthodontics in Daily Practice.* Philadelphia, Pa: JB Lippincott; 1974:183–196.  
 6. Nahoum HI. Anterior open bite: a cephalometric analysis and suggested treatment procedures. *Am J Orthod.* 1975; 67:513–521.  
 7. Boyd RL. Esthetic orthodontic treatment using the Invisalign® appliance for moderate to complex malocclusions. *J Dent Educ.* 2008;72:948–967.  
 8. Greenlee GM, Huang GJ, Chen SS, Chen J, Koepsell T, Hujoel P. Stability of treatment for anterior open-bite malocclusion: a meta-analysis. *Am J Orthod.* 2011;139: 154–169.  
 9. Cerci V, Cerci BB, Meira TM, Cerci TX, Tanaka OM. Eight-year stability of a severe skeletal anterior open bite with a hyperdivergent growth pattern treated with an edgewise appliance and chin cup therapy. *Am J Orthod.* 2012;141: 65–74.  
 10. Boyd RL. Complex orthodontic treatment using a new protocol for the Invisalign®. *Appliance J Clin Orthod.* 2007; 41:525–547; quiz, 523.  
 11. Schupp W, Haubrich J, Neumann I. Treatment of anterior open bite with the Invisalign®. *J Clin Orthod.* 2010;44: 501–507.

Table 1. Cephalometric Analysis

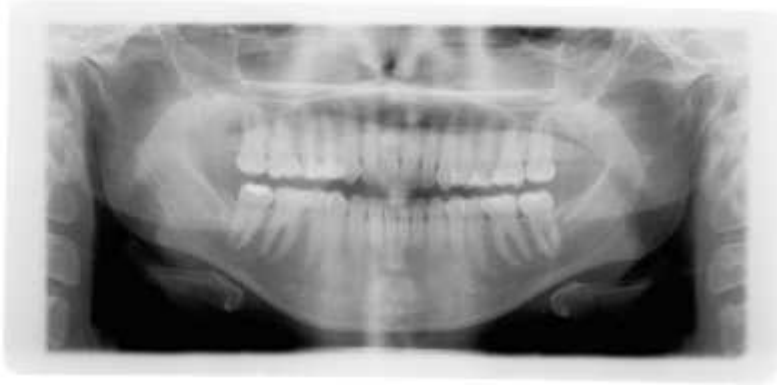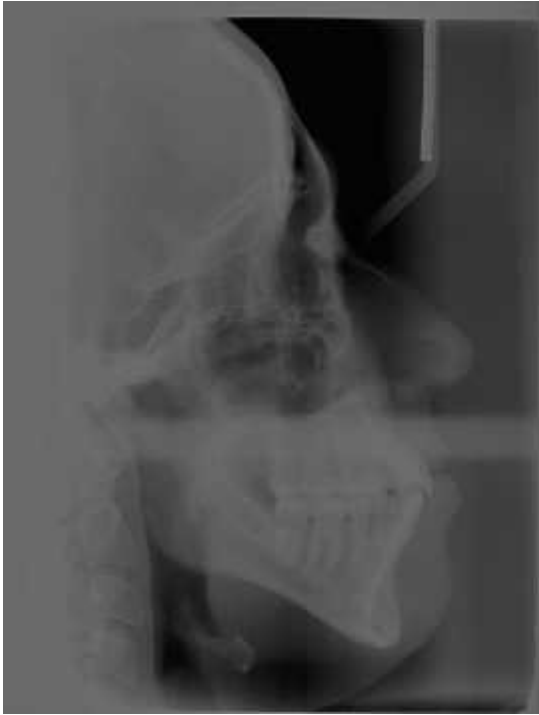Measurement	Initial	Final
SNA (°)	86.9	84.9
SNB (°)	77.2	77.3
ANB (°)	9.7	7.5
Maxillary skeletal (A-Na-Perp), (mm)	13.9	–2.6
Mandibular skeletal (Pg-Na-Perp), (mm)	–12.1	–37.8
Wits appraisal, (mm)	13.1	3.6
FMA (MP-FH) (°)	37.2	42.2
MP-SN (°)	47.0	46.1
Palatal-mandibular angle, (°)	37.3	40.1
Palatal-occlusal plane (PP-OP) (°)	7.6	13.9
Mandibular plane to occlusal plane (°)	29.7	26.2
U-incisor protrusion (U1-Apo), (mm)	20.3	20.6
L1 protrusion (L1-Apo), (mm)	13.0	14.6
U1-palatal plane	119.5	110.2
U1-occlusal plane	52.9	55.9
L1-occlusal plane	53.8	60.2
IMPA (°)	96.5	93.5



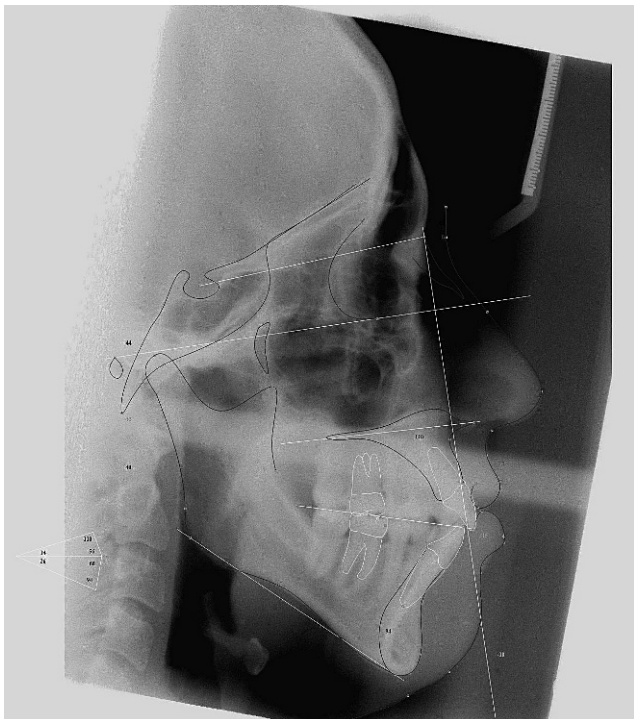
**Figure 8.** Posttreatment photographs.



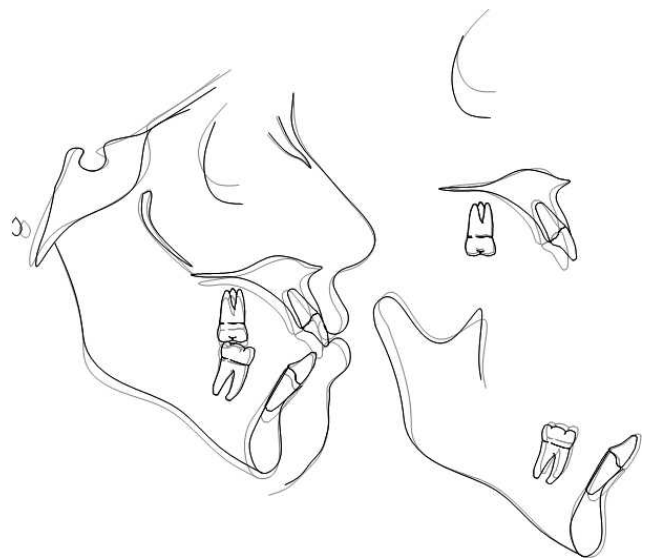
**Figure 9.** Intraoral pictures at the end of treatment.



**Figure 10.** Posttreatment radiographs.



**Figure 11.** Cephalometric tracing at the end of treatment.



**Figure 12.** Superimposition pre- and posttreatment cephalometric tracings.